

COMPARATIVE STUDY OF THE EFFECTS OF ADRENALINE VERSUS TRANEXAMIC-ACID ON SPLIT THICKNESS SKIN GRAFT DONOR SITE

¹*Weam Ali, ²Firas Melhem, ³Safwan Yousef

¹Department of plastic and reconstructive surgery, Tishreen university hospital, Lattakia, Syria.

²Department of Plastic and Reconstructive Surgery, Proffesor, Tishreen University Hospital, Lattakia Syria.

³Department of Orthopedic Surgery, Professor, Tishreen University Hospital, Lattakia, Syria.

Article Info

Article Received: 19 February 2024

Article Revised: 10 March 2024

Published on: 01 April 2024



*Corresponding author:

Weam Ali

Department of plastic and reconstructive surgery, Tishreen university hospital, Lattakia, Syria.

Yara.sulieman2@gmail.com

ABSTRACT

Objective: The need to find effective methods that enable us to control bleeding at the sites of split thickness skin graft extraction by comparing the effect of adrenaline and tranexamic acid application on these sites.

Material and Methods: A prospective randomized clinical trial conducted in the Reconstructive Surgery Department at Tishreen University Hospital, from November 2022 to November 2023. At the end of the study, 34 patients were included.

After taking the patient's consent, clinical history, and filling out the form, the patients were randomly divided into two groups.

The first group: The patients who had the graft site infiltrated with a lidocaine-adrenaline solution at a concentration of 1/100,000.

The second group: The patients who had the graft site infiltrated with lidocaine 2% only, with tranexamic acid given intravenously half an hour before surgery at a dose of 10 mg/kg, then a gauze impregnated with tranexamic acid was applied immediately after harvesting the graft for ten minutes.

Results: The average age was similar in both groups (about 30 years). The mean operative time was similar in the two groups and was less in the TXA group, but without a statistically significant difference.

Most of grafts were harvested from the lower extremity, which is the most common site for harvesting split thickness skin graft. When studying the incidence of bleeding in the study patients, it was found that the group of patients who were given TXA had less bleeding compared to the patients who were prepared with adrenaline and lidocaine, with a statistically significant difference, and thus TXA reduces the incidence of bleeding at the site of the partial-thickness skin graft.

When studying the need for dressing change, we found that patients who were given intravenous TXA and had a gauze impregnated with TXA needed to change the dressing less often when compared to the rest of the study patients. Thus, the use of TXA reduces the need to change the dressing during the first day of surgery.

We did not find a statistically significant difference between the two groups in terms of hemoglobin after surgery or the need for blood transfusion.

We found that the use of TXA does not cause complications or serious or life-threatening side effects that prevent its use, as most of the effects that occurred were pain and edema, and their percentage was similar to that of patients in the second group.

Conclusion: TXA is considered a cheap substance that has a good effect in reducing bleeding during and after surgery and does not cause side effects that prevent its use.

KEYWORDS: Reconstructive surgery, split thickness skin graft, bleeding, transaminase acid.

INTRODUCTION

Grafting operations are considered one of the basic options in the reconstructive ladder, and we resort to them to close tissue defects of various sizes, whether resulting from traumas, burns, or malignancies.^[1] The place where the graft is harvested requires special attention, both in terms of choosing its location on the surface of the body and dealing with it in the postoperative period until complete healing.^[2] Bleeding from partial-thickness graft donor site is one of the most prominent problems facing grafting operations of wide areas of the body, such as burn patients in particular. There is an increasing interest in reducing blood loss in the perioperative period due to the risks associated with blood group incompatibility, viral infection, in addition to the difficulties in getting fresh blood. Tranexamic acid (an activated plasminogen inhibitor), which is used in many surgeries (cardiac surgery), is a hemostatic agent whose application is rapidly increasing^[4]. The primary objective of this research is to study the effectiveness of Tranexamic acid in reducing the amount of blood loss to the minimum in the perioperative period to prevent the need for blood transfusion and to prevent subsequent complications by comparing a number of partial-thickness graft patients who were given TXA intravenously by systemic route and topical application with impregnated gauze in the Partial-thickness graft donor sites.

OBJECTIVES

- **Main objective:** Study the efficacy of tranexamic acid in reducing blood loss in split thickness skin graft donor site.
- **Secondary objectives:** Comparison between the two groups in:
 1. The need of dressing change within 24 hours after surgery.
 2. Success of grafting.
 3. Success of epithelialization in donor site.

MATERIALS AND METHODS

- **Study design:** Prospective randomized controlled clinical trial.
- **Study period and place:** The study was conducted in the Reconstructive Surgery Department at Tishreen University Hospital, Lattakia, Syria, from November 2022 to November 2023.
- **Study sample:** A total of 34 patients were included in our study and divided into two group.
 1. The first group: The patients who had the graft site infiltrated with a lidocaine-adrenaline solution at a concentration of 1/100,000.
 2. The second group: The patients who had the graft site infiltrated with lidocaine 2% only, with tranexamic acid given intravenously half an hour before surgery at a dose of 10 mg/kg, then a gauze

impregnated with tranexamic acid was applied immediately after harvesting the graft for ten minutes.

- **Inclusion criteria:** All patients who had a skin defect and can be repaired with a split thickness skin graft.
- **Exclusion criteria**
 1. Multiple traumas and icu patients.
 2. Chronic illnesses prevent healing of the graft and the donor site
 3. (Diabetes, patients who are taking long-acting systemic steroids).
 4. Previous sensitivity to TXA.
 5. Previous DVT or pulmonary embolism.
 6. Hepatic or renal failure.
 7. Hematologic disorders.

METHODOLOGY

Preoperative

We have taken a full history including the cause of defect, its site on the body, its size, the past history of any chronic diseases especially hematologic illnesses, allergic reactions, recurrent infections and the history of medical treatment especially anti-coagulants.

Written Informed consent was taken from all patients for the planned procedure in a perform approved by our institutional ethical committee.

Operative procedure

- All surgeries were done under general anesthesia with control of systemic blood pressure.
- For the first group of patients: a solution of lidocaine 2% and adrenaline in a concentration of 1:100000 was infiltrated in the donor site before taking the graft.
- For the second group of patients: the patient was given tranexamic acid intravenously in a dose of 10 mg/kg, half an hour before the surgery.

The donor site was infiltrated with lidocaine 2% before taking the graft, and after taking the graft a gauze impregnated in tranexamic acid was applied on it for 10 minutes.

- In the two groups, skin graft was harvested by using the dermatome in the same thickness (about 0,75 mm) and in a size correlate with the defect area size.
- A dressing consists of one fucidate gauze on the top of the donor site, three layers of gauze tied with a dressing bond.
- Photos of the donor site were taken before and after dressing and 24 hours after surgery and after 14 days when changing the dressing to estimate epithelialization.
- Photos of the defect were taken before grafting, after grafting and on the 5th day after surgery to estimate success or failure of the grafting.

STATISTICAL ANALYSIS

-Data were entered, checked, and analyzed using Spss 2015 version n22.
 -X² (chi-squared) was used for difference between qualitative variables.
 -T-student was used for difference between quantitative variables.

RESULTS

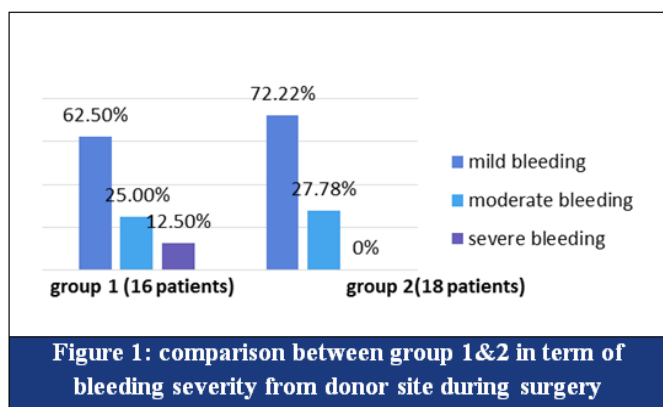
-This study was conducted on 34 patients, 21 were men (61,86%) ,and 13 were women (38,24%). The majority of patients were in the fourth decade.

At the time of the surgery:

In group 1: 10 patients had mild bleeding (62,50%).
 4 patients had moderate bleeding (25%).
 2 patients had severe bleeding (12,5 %).

In group 2: 13 patients had mild bleeding (72,23%).
 5patients had moderate bleeding (27,78%).
 No one had severe bleeding.

With a difference statistically important between the two groups. (P-value = 0,001). [Figure 1]



In the 24 hours after surgery 4 patient of group1 needed to change dressing in the donor site, versus 12 patients didn't have any need.

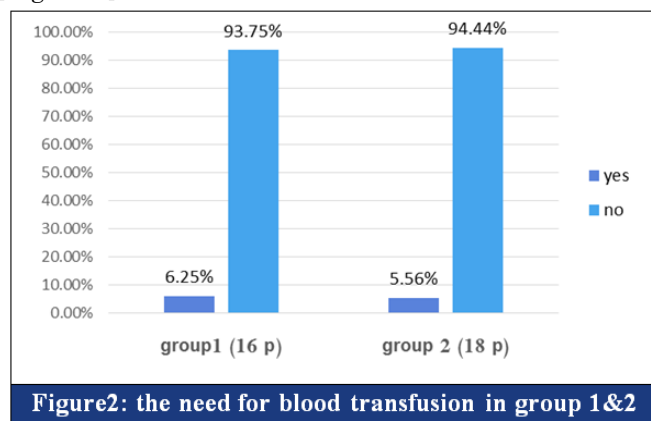
In group2 only 1patient needed to change the donor site dressing versus 17 patients didn't have any need, with a difference statistically significant important (P-value =0,001). [Table 1]

Need for dressing change	Group1(16 p)	Group 2(18p)
Yes	4(25%)	1(5.56%)
No	12(75%)	17(94.44%)
P – Value	0.001	

The rate of grafting success was 93,75% in group 1, and 94,44% in group 2 without statistically significant difference between the two groups (p-value = 0,563). [Table 2].

Grafting success	Group1(16 p)	Group 2(18p)
Yes	15(92.75%)	17(%94.44)
No	1(6.25%)	1(%5.56)
P – Value	0.563	

One patient of each group needed blood transfusion after surgery, and that was not statistically important [Figure 2].



In group 1: we observed a slow re-epithelialization process at the donor site when evaluated at day 14 after surgery in 3 patients.

In group 2: 2 patients had slow re-epithelialization patients.

The difference was not statistically important (p-value= 0.55).

DISCUSSION

After surgical procedures, attempts to reduce postoperative bleeding are of great importance.

Blood loss associated with surgical interventions can lead to several complications. Therefore, minimizing perioperative bleeding is critical to improve overall survival.^[6]

Several interventions have been found to successfully reduce surgical bleeding, including the antifibrinolytic agents. After aprotinin was withdrawn from the market in 2008, TXA remained the most commonly used medication.

The safety and efficacy of TXA has been well studied in other specialties. TXA has been rarely used in plastic surgery, except in craniofacial procedures.

Since the last review, the number of articles examining the use of TXA has doubled either in plastic or reconstructive surgery.

Our study showed that TXA has more important role in reduce bleeding in split-thickness skin graft donor sites in comparison with adrenaline, with a statistically important difference (p-value= 0,001).

There was a statistically important difference between the two groups in the need of dressing change in the first 24 hours after surgery (p-value= 0,001).

In our study we didn't observe any effects on re-epithelialization process and the difference between the groups was not statistically important (p-value =).

Ajai et al^[8] studied the effect of a single dose intravenous of TXA on blood loss in tangential excision of burn wounds ,their study showed that TXA reduce blood lose ber unit burn area of tangential excision in <30% TBSA burn ,but no significant effect on postoperative HB and transfusion.

Nicolas M.A et al ^[9] studied the combined effect of IV and local TXA in power assisted liposuction mammoplasty technique and they found a decreased dermal bleeding in TXA group and less ecchymosis in postoperative evaluation.

Mohammad A.G et al^[10] studied the efficacy of tranexamic acid on intraoperative bleeding , postoperative eyelid edema , and postoperative periorbital ecchymosis in rhinoplasty .

Their study showed that administration of 10 mg/kg TXA had a significant effect in decreasing the intraoperative bleeding rate, eyelid edema and periorbital ecchymosis in the rhinoplasty with minimal side effects.


CONCLUSION

- TXA effectively reduced bleeding in split thickness skin graft donor sites and thus reducing blood loss in the perioperative period.
- It's local application on the donor site had no bad effect on re-epithelialization.
- No thrombotic events were observed with its systemic usage.
- More studies with a large sample size are needed to evaluate.

REFERENCES

1. Essenstial of plastic surgery: 8th edition.
2. Amjad A, Jack Mc, Catherine R,H. Utilities of splite – thickness skin grafting for male genital reconstruction.

3. Rannikko A, Pétas A, Taari K. Tranexamic acid in control of primary hemorrhage during transurethral prostatectomy. *Urology*. 2004 Nov; 64(5):955-8. [PubMed]
4. Schutgens REG, Lisman T. Tranexamic Acid Is Not a Universal Hemostatic Agent. *Hemasphere*. 2021 Aug;5(8):e625. [PMC free article] [PubMed]
5. Morrison JJ, Dubose JJ, Rasmussen TE, Midwinter MJ. Military Application of Tranexamic Acid in Trauma Emergency Resuscitation (MATTERS) Study. *Arch Surg*. 2012 Feb; 147(2):113-9. [PubMed]
6. Gharaibeh A, Savage HI, Scherer RW, Goldberg MF, Lindsley K. Medical interventions for traumatic hyphema. *Cochrane Database Syst Rev*. 2013 Dec 03;12(12):CD005431. [PMC free article] [PubMed]
7. Srinil S, Jaisamrarn U. Treatment of idiopathic menorrhagia with tranexamic acid. *J Med Assoc Thai*. 2005 Oct;88 Suppl 2:S1-6. [PubMed].
8. Ajai K.S., Parmod Kumar, Mohsina Subair, Ramesh Kumar Sharma, Effect of single dose intravenous tranexamic acid on blood loss in tangential excision of burn wounds — A double blind randomised controlled trial, *Burns*, Volume 48, Issue 6, 2022, Pages 1311-1318, ISSN 0305-4179, <https://doi.org/10.1016/j.burns.2021.08.021>.
9. Nicolas M Abboud, Ayush K Kapila, Sofie Abboud, Elie Yaacoub, Marwan H Abboud, The Combined Effect of Intravenous and Topical Tranexamic Acid in Liposuction: A Randomized Double-Blinded Controlled Trial, *Aesthetic Surgery Journal Open Forum*, Volume 3, Issue 1, January 2021, ojab002, <https://doi.org/10.1093/asjof/ojab002>
10. Mohammad Ali Ghavimi, Koroush Taheri Talesh, Arezoo Ghoreishizadeh, Mir Amir Chavoshzadeh, Ali Zarandi, Efficacy of tranexamic acid on side effects of rhinoplasty: A randomized double-blind study, *Journal of Cranio-Maxillofacial Surgery*, Volume 45, Issue 6, 2017, Pages 897-902, ISSN 1010-5182, <https://doi.org/10.1016/j.jcms.2017.03.001>.

 <p>WJIMS World Journal of Internal Medicine and Surgery</p> <p>Editor in Chief</p> <p>www.wjims.com</p>	<p>Assets of Publishing with us</p> <ul style="list-style-type: none"> ➤ Global archiving of articles ➤ Immediate, unrestricted online access ➤ Rigorous Peer Review Process ➤ Authors Retain Copyrights ➤ Unique DOI for all articles <p>https://wjims.com/</p>
--	---